



CE

Article #1 (1.5 contact hours)

Refereed Peer Review

## KEY FACTS

- Differentiation between pituitary- and adrenal-dependent hyperadrenocorticism is crucial for determining treatment options and providing a prognosis.
- Approximately 50% of pituitary tumors are estimated to continue growing throughout an animal's life, possibly leading to problems caused by compression of surrounding neurologic structures.
- Approximately 50% of adrenocortical tumors are benign and 50% malignant.
- Although animals with benign tumors have a better prognosis, even animals with malignant tumors may survive long term if metastases are not present at surgery and all gross tumors can be resected.

# Surgical Treatment of Canine Hyperadrenocorticism

Auburn University

Todd W. Axlund, DVM, DACVIM (Neurology)

Ellen N. Behrend, VMD, PhD, DACVIM (Internal Medicine)

Alabama Veterinary Specialists

Bessemer, AL

James T. Winkler, DVM, MS, DACVS

**ABSTRACT:** Hyperadrenocorticism is a common canine disorder resulting from a functional pituitary or adrenocortical tumor. Eighty percent to 85% of canine cases of hyperadrenocorticism are caused by a tumor in either the anterior or intermediate lobe of the pituitary. Differentiation tests (e.g., endocrine tests, advanced imaging studies) are designed to distinguish between pituitary- and adrenal-dependent hyperadrenocorticism. Treatment includes medical and surgical options. However, surgical removal of the tumor provides the strongest possibility of a cure and elimination of the threat of malignant transformation, tumor metastasis, and invasive growth.

**H**yperadrenocorticism is a common canine disorder resulting in a constellation of clinical signs caused by overproduction of cortisol. The disease is further classified as follows:

- **Pituitary-dependent hyperadrenocorticism (PDH)**—Excess cortisol is produced as a result of inappropriate secretion of adrenocorticotrophic hormone (ACTH) from the pituitary.
- **Adrenal-dependent hyperadrenocorticism (ADH)**—Excess cortisol is produced as a result of a functional tumor on the adrenal cortex.

Ideally, therapy for canine hyperadrenocorticism should be dictated by the specific cause.

## INDICATIONS FOR HYPOPHYSECTOMY

Eighty percent to 85% of the cases of spontaneous hyperadrenocorticism in dogs are a result of a functional pituitary tumor or hyperplasia, either in the anterior pituitary (85% of PDH cases) or the intermediate lobe (15% of PDH cases). A pituitary tumor is responsible for PDH in 90% of the cases.<sup>1</sup> This disease

is also found in humans, cats, and horses, although the location of the pituitary tumor differs between species.<sup>2</sup>

Unfortunately, it is unclear whether a medication currently exists that consistently decreases ACTH production from both the anterior pituitary and intermediate lobes. Selegiline (Anipryl, Pfizer Animal Health) decreases secretion from the intermediate lobe, but whether it does so from the anterior pituitary is debatable.<sup>3-5</sup> In dogs with pituitary tumors, the mainstay of therapy in the United States consists of decreasing the ability of the adrenal cortex to respond to ACTH.<sup>6</sup> This is most commonly done by chemical ablation of the adrenal cortex with mitotane. Mitotane can be costly, requires a dosage tailored to individual animals, and is associated with side effects in 25% to 30% of dogs during maintenance and induction.<sup>7</sup> Monitoring of the drug's effects is essential, requiring frequent visits to a veterinary facility. Additionally, because mitotane has no effect on the pituitary, the pituitary tumor could grow unchecked, ultimately resulting in neurologic dysfunction related to compression of surrounding structures. In one study, 6 of 13 dogs had visible pituitary growth, as determined by magnetic resonance imaging (MRI), 1 year after diagnosis and medical treatment was initiated for PDH.<sup>8</sup> Also, two dogs developed neurologic dysfunction within 1 year of diagnosis as a result of tumor growth. A better approach would be surgical removal of the pituitary tumor early in the disease course.

The role of the surgeon in pituitary disease has been well established in the human medical field. The first pituitary surgeries, however, were performed and perfected using dogs as research subjects. The first description of a pituitary removal (hypophysectomy) and the clinical outcome was made by Horsely in 1886 and involved two dogs. In 1914, Harvey Cushing, the eminent founder of the field of neurosurgery, popularized the transsphenoidal approach to the pituitary.<sup>9</sup> This basic technique is still in common use today.

The first hypophysectomy in dogs for treating PDH was reported in 1968.<sup>10</sup> Since then, a variety of surgical techniques have been established and studied for use in dogs.<sup>11-14</sup> The main goal of the procedure is to remove the pituitary adenoma. However, because the adenoma is often difficult or impossible to differentiate from normal pituitary tissue during the surgical procedure, the entire gland is removed. Various techniques have been established to maximize visualization of the pituitary while minimizing damage to surrounding structures. Generally, all of the published techniques use the basic transsphenoidal approach with minor variations.

Not surprisingly, very few clinical hypophysectomies were performed and reported after the initial surgeries in 1968. The major problem was localization of the

pituitary. It is imperative that the surgical approach be precise because a large vascular cavernous sinus; the arterial cerebral circle (Circle of Willis); the oculomotor, trochlear, and abducent nerves; and ophthalmic branch of the trigeminal nerve surround the pituitary. The gland, which is located in a bony saucer-shaped sella turcica, varies in position depending on the dog's head conformation. Therefore, a surgeon is unable to use bony landmarks to consistently locate the pituitary in every breed of dog. Not until the advent of advanced imaging modalities, such as computed tomography (CT) and MRI, could the pituitary be easily and consistently visualized and localized. Surgical treatment of PDH is becoming more available now because of the accessibility of CT and MRI.<sup>14</sup> Definition of the position of the pituitary relative to external bony landmarks seen by imaging allows careful surgical planning and precise exploration of the sella turcica.

### INDICATIONS FOR ADRENALECTOMY

ADH accounts for 15% to 20% of dogs with hyperadrenocorticism.<sup>1</sup> Unilateral functional adrenal tumors may be treated with medical therapy, usually mitotane, or adrenalectomy. However, adrenalectomy has many advantages over medical management.<sup>3</sup> Surgery provides the opportunity for cure, whereas medical therapy requires lifelong medication, close monitoring by the owner, and intermittent endocrine testing for dose adjustments. In addition, mitotane is not as effective for treating ADH as it is for PDH, the drug does not appear to affect metastatic disease, and some dogs may not tolerate the dosages required.<sup>3</sup>

Bilateral adrenalectomy is indicated for treating bilateral adrenal tumors, which are rare and may involve any combination of cortical tumors, pheochromocytomas, or hyperplasia. In one study of adrenal tumors, 2 of 36 dogs had bilateral adrenocortical tumors.<sup>15</sup> Bilateral adrenalectomy is rarely performed in dogs with PDH but may be indicated in patients that cannot tolerate medical management and in which hypophysectomy cannot be performed.

### DIFFERENTIATION TESTS

Although they add expense and time, endocrinologic differentiating tests (i.e., high-dose dexamethasone suppression test [HDDST], endogenous ACTH measurement) or imaging techniques (e.g., ultrasonography, CT, MRI) should be conducted to distinguish PDH from ADH because this determines treatment options and prognosis. If surgery is an option, knowing the location of the tumor is essential. Medical therapy can also vary with the type of hyperadrenocorticism. For example, selegiline is not a therapeutic option for

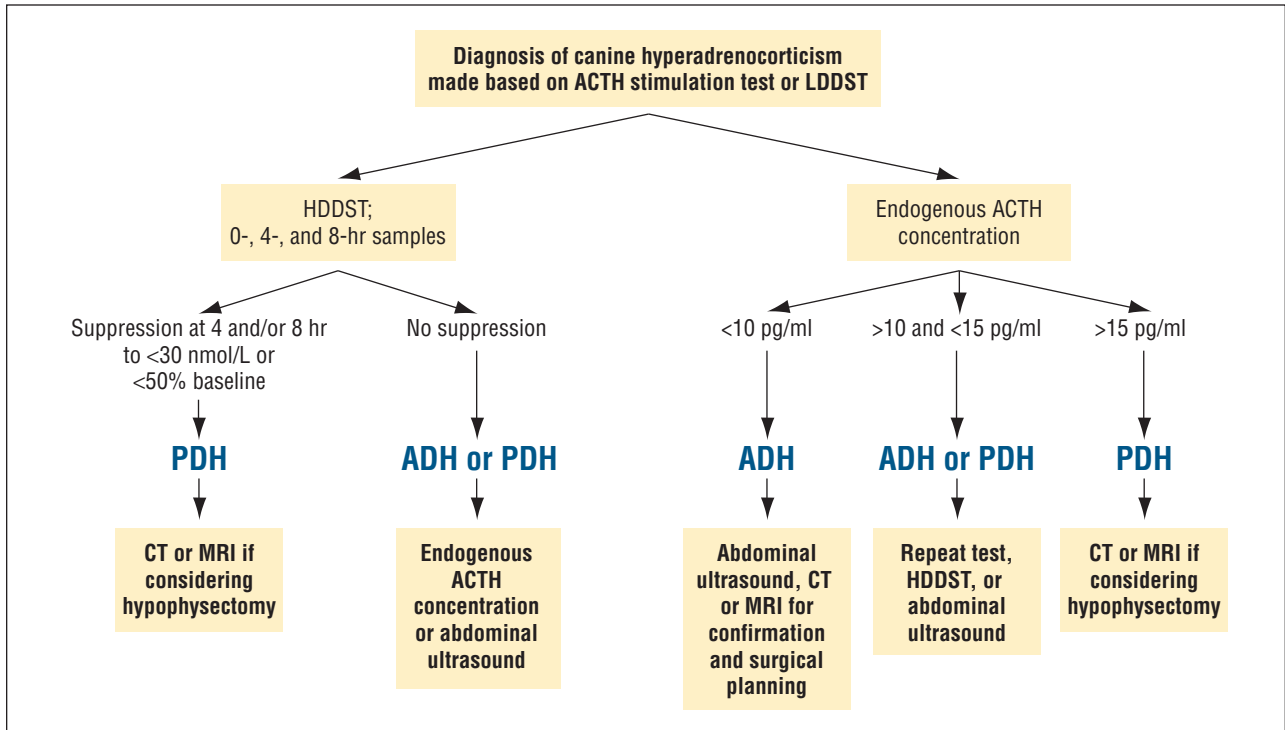


Figure 1—Diagnostic flowchart for the differentiation of PDH and ADH.

ADH, and the therapeutic approach with mitotane is different for PDH and ADH. Unfortunately, no test for the diagnosis or differentiation of hyperadrenocorticism is perfect. Understanding the advantages and disadvantages of each test, however, allows selection of a test most likely to provide the desired information.

Please note that the following laboratory values are from the Auburn University Endocrine Diagnostic Laboratory. When interpreting results, always use normals established by the laboratory that conducted the test.

### High-Dose Dexamethasone Suppression Test

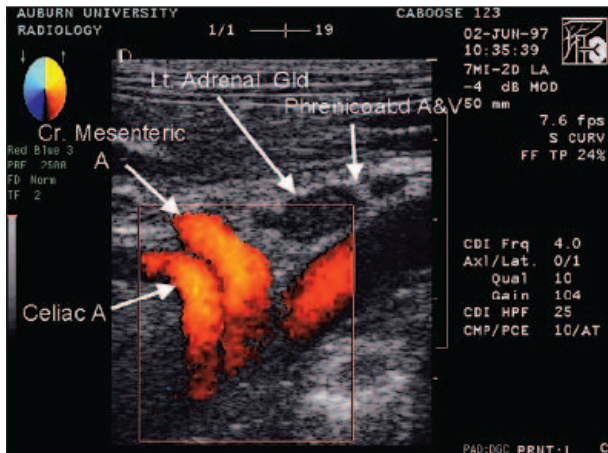
Normally, dexamethasone feeds back onto the pituitary, turning off ACTH secretion. When systemic ACTH concentration falls, the stimulus to the adrenal cortex diminishes and cortisol release decreases. Thus at 4 and 8 hours after dexamethasone, plasma cortisol concentration is low (i.e., <30 nmol/L [approximately 1 µg/dl]). With PDH, the pituitary tumor is relatively resistant to feedback. In the low-dose dexamethasone suppression test (LDDST), some secretion of ACTH persists despite the dexamethasone injection; thus cortisol release continues and there is inadequate suppression. For patients with ADH, endogenous ACTH is already suppressed because of cortisol secretion from the tumor. Furthermore, the adrenal tumor secretes cortisol autonomously; ACTH is not required. Administration of an exogenous glucocorticoid has no

appreciable effect on ACTH or cortisol secretion, and there is no suppression. In comparison, a high dose of dexamethasone may overcome the resistance to feedback in dogs with PDH; as a result, ACTH and cortisol secretion are suppressed. For dogs with ADH, a high dose of dexamethasone will still have little to no effect on cortisol secretion. Therefore, HDDST suppression of serum cortisol concentration to either less than 30 nmol/L or less than 50% of baseline at 4 and/or 8 hours after dexamethasone administration is consistent with PDH (Figure 1).<sup>16</sup>

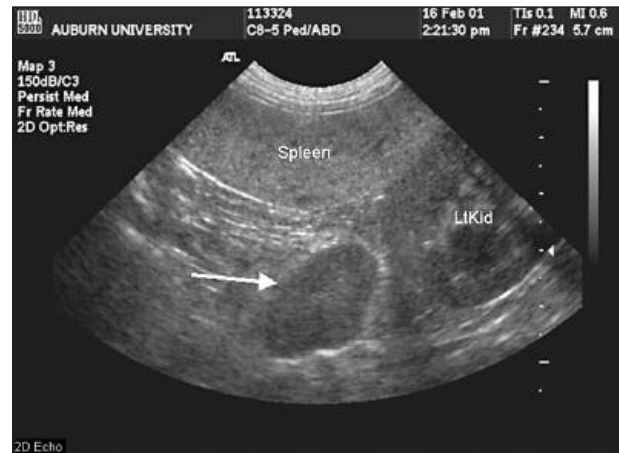However, cortisol concentration is not suppressed in approximately 30% of dogs with PDH.<sup>17</sup> Because lack of suppression can be seen with PDH or ADH, an HDDST can never confirm the presence of an adrenal tumor. If a dog's cortisol concentration is not suppressed on the HDDST, there is an approximately 50% chance that it has PDH or ADH, and another differentiation test must be done. Also, if the LDDST was used as the screening test and it did not provide a differentiation, the HDDST is also not likely to do so<sup>16</sup> and the endogenous ACTH measurement would be a better test.

### Endogenous ACTH Measurement

Because dogs with hyperadrenocorticism can have a normal endogenous ACTH concentration,<sup>18</sup> endogenous ACTH measurement is recommended only after a diagnosis of hyperadrenocorticism has been established.



**Figure 2**—Color flow Doppler ultrasound of a normal left adrenal gland demonstrating the phrenicoabdominal vein coursing over the gland.



**Figure 3**—Ultrasonographic examination of an enlarged left adrenal gland (arrow) situated craniomedial to the left kidney (LtKid).

In dogs with PDH, endogenous ACTH concentration should be normal to elevated because of secretion from the pituitary tumor. In dogs with ADH, the endogenous ACTH concentration should be below normal because of feedback on the pituitary. An advantage of this test is that it can confirm the presence of ADH. Unfortunately, a gray zone exists between values consistent with PDH and those consistent with ADH. For concentrations that fall in the gray zone, differentiation is impossible (Figure 1).

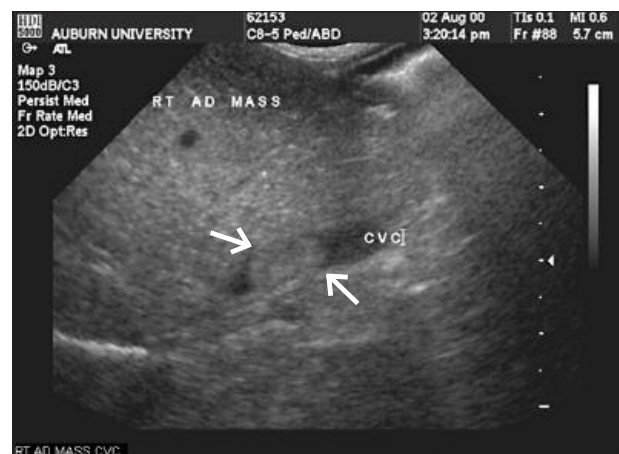Of 292 tests in 245 dogs, 240 (82.2%) were diagnostic for either PDH or ADH. With repeat testing when the initial result was in the gray zone, 235 of 245 dogs (95.9%) had a definitive differentiation.<sup>17</sup> Unfortunately, there is no way to predict when a serum ACTH concentration will be in the diagnostic range.

### Radiography

Abdominal radiography can be helpful in differentiation if an adrenal tumor is found. Of 94 tumors in 88 dogs (six dogs had bilateral tumors), 53% were detected because of calcification within the tumor and/or visualization of a mass.<sup>17</sup> Both adenomas and carcinomas can contain mineral densities or appear as a mass cranial to the kidney. A pattern of diffuse mineralization is usually associated with adrenal neoplasia, but discrete, well-margined mineralization can develop in clinically normal animals.<sup>19</sup> Mineralization may also rarely occur in the adrenal glands of dogs with PDH.<sup>20</sup> Interestingly, in the dogs with bilateral tumors, only one tumor was visualized by abdominal radiography.<sup>21-23</sup>

### Abdominal Ultrasonography

Ultrasonography may have more application in differentiation than does radiography. Small or noncalcified



**Figure 4**—Ultrasonographic examination of a hyperechoic mass (arrows) within the caudal vena cava (CVC). Ultrasonography cannot differentiate tumor involvement from thrombus.

adrenal tumors can be detected more easily using ultrasonography in animals with ADH, and bilateral adrenal enlargement can be visualized in dogs with PDH. The technique is limited, however, by difficulty in visualizing the adrenal glands because of size, retroperitoneal position, or the presence of other pathologic conditions.<sup>24,25</sup> The right adrenal gland is more difficult to visualize than the left.<sup>25-27</sup> Asymmetry within a single gland or between glands can also exist normally and should not be mistaken for the presence of an adrenal tumor.<sup>20</sup>

In dogs with PDH, bilateral adrenal enlargement may be found. Typically, the parenchymal texture and homogeneity appear normal, but heterogeneity with variably sized focal areas of increased echogenicity may exist (Figure 2).<sup>20</sup> Although ultrasonography defines

location, size, and organ involvement of adrenal tumors more precisely than radiography alone, they are not always seen. Of 79 tumors, 86% were found.<sup>17</sup> When the tumor was missed, the affected adrenal gland appeared normal or was not even visualized.<sup>22,23,26</sup> The tumor may be hypo-, iso-, or hyperechoic compared with the renal cortex or it may have mixed echogenicity. Mineralization or areas of necrosis or hemorrhage can be seen (Figure 3).<sup>28,29</sup> The adrenal gland may also simply appear enlarged.<sup>22</sup> Cases of bilateral adrenal tumors can be mistaken for bilateral adrenal hyperplasia, falsely providing a diagnosis of PDH.<sup>22</sup>

Differentiation between an adrenal adenoma and carcinoma is unlikely with ultrasonography because they can appear similar. Neither echogenicity nor the presence of mineralization can be used. Lesions suggestive of metastasis may be found, however, especially in the liver.<sup>23,29</sup> Evidence of invasion into the vena cava is suggestive of a carcinoma or thrombus (Figure 4). Lack of this finding does not mean that invasion is absent, however, because it can be missed.<sup>30,31</sup>

### Computed Tomography

Abdominal CT is an even more sensitive way of assessing adrenal gland structure and has correctly differentiated between bilateral or unilateral enlargement in 36 dogs.<sup>17</sup> Hyperplastic glands may appear slightly rounded compared with normal,<sup>32</sup> mineralization not apparent on radiography may be found, and hypoplasia of a gland contralateral to an adrenal tumor can be seen,<sup>33,34</sup> but this technique still has limitations. Enlargement is not always apparent, and the glands may be of normal size.<sup>33</sup> It is likely impossible to differentiate

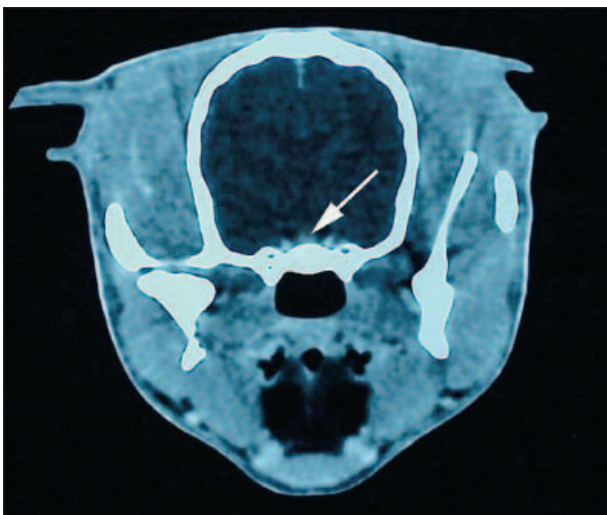
between benign and malignant masses on the basis of size, shape, or pre- and postcontrast assessment.<sup>32</sup> Lastly, vascular invasion can be difficult to distinguish. Enlarged adrenal glands may adhere to or compress the vena cava, suggesting invasion when it is not present.<sup>32,33,35</sup>

Standard and dynamic CT can also be used for pituitary assessment. With standard CT, pituitary tumors are typically located in the sella turcica and extend dorsally and laterally along the base of the brain. Bilaterally symmetric hydrocephalus, a mass effect, peritumoral edema, and mineralization may be seen.<sup>36,37</sup> Most tumors have minimal to marked contrast enhancement and well-defined margins.<sup>32,36,38</sup> Small pituitary tumors may not be visualized with or without contrast,<sup>32</sup> thus absence of a visualized mass does not rule out PDH.<sup>32,36</sup>

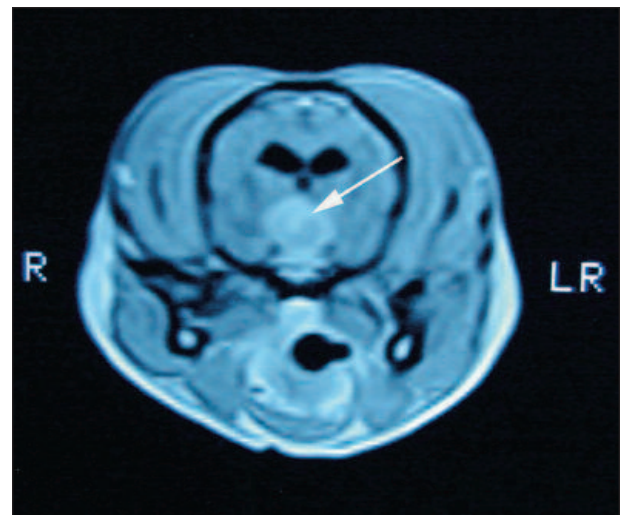
Dynamic CT is more sensitive than conventional contrast-enhanced CT.<sup>38</sup> Two distinct enhancement patterns are seen in normal canine pituitaries: early intense enhancement, called the *pituitary flush*, followed by peripheral rim enhancement (Figure 5).<sup>39,40</sup> Pituitary size relative to brain size (P:B ratio) can also be assessed.<sup>41</sup> In dogs with PDH, abnormalities can be visualized as an increase in P:B ratio or displacement or disruption of the pituitary flush, but results may still be normal; thus sensitivity is not 100%.<sup>38</sup> If hypophysectomy is being considered for therapy, the extra sensitivity of dynamic CT may be helpful to ensure the correct treatment is being provided. In other cases, dynamic CT may not be warranted.

### Magnetic Resonance Imaging

MRI has not been used as a differentiation test but has been used to assess the size of a pituitary mass in



**Figure 5**—CT image of a normal pituitary (*arrow*) after administration of an IV contrast agent.



**Figure 6**—MRI of a large contrast-enhancing mass (*arrow*) in the pituitary area.

known cases of PDH. In two studies of dogs with PDH that were showing unexplained neurologic signs, a pituitary mass was seen in all dogs. Typically, these masses are greater than 1 cm in diameter but may be smaller.<sup>42,43</sup> Most tumors are contrast enhancing (Figure 6).<sup>42,43</sup>

### PREOPERATIVE PLANNING

Patient selection is a primary concern when considering surgery for treating hyperadrenocorticism. First and foremost, the surgeon must be assured of the location of the tumor using endocrinologic and imaging data. Pituitary tumors larger than 1 cm are generally not resectable, and other treatment modalities should be considered. Most pituitary adenomas are smaller than 1 cm in diameter, however, and are considered amenable to surgical removal.

A complete blood cell count, serum biochemical panel, urinalysis, and chest radiography are conducted to identify any disease process that would render a dog unfit for a major surgical procedure. Because most animals with hyperadrenocorticism are older than 7 years of age,<sup>1</sup> general health screening is an important consideration.

For dogs with ADH, abdominal ultrasonography may be used (if no imaging studies were used for differentiation between PDH and ADH) to evaluate adrenal size and degree of local tissue invasion and identify metastatic disease. Although two studies reported a low rate of metastasis at the time of surgery,<sup>15,44</sup> an incidence as high as 50% was reported in another.<sup>45</sup> Extensive local invasion involving the caudal vena cava may occur in as many as 21% of dogs with carcinomas, but renal vein involvement necessitating nephrectomy is rare.<sup>45</sup>

If a nephrectomy is necessary, the ability of the patient to live with only the contralateral kidney must be ensured. If renal disease is suspected from blood chemistry and urinalysis, further diagnostics to determine kidney function should be conducted. Excretory urography and abdominal ultrasonography provide valuable information concerning kidney disease, and nuclear scintigraphy provides quantitative assessment of function for each kidney.<sup>46-48</sup>

To help control hyperadrenocorticism before surgery, ketoconazole therapy may be initiated. Ketoconazole may improve clinical signs in affected patients. The initial dosage is 5 mg/kg PO bid for 7 days, and this may be increased to 10 mg/kg PO bid if no severe adverse effects are noted.<sup>49</sup> Alternatively, mitotane can be used.

### HYPOPHYSECTOMY

All accepted surgical techniques for hypophysectomy approach the pituitary ventrally. The gland itself lies in a small depression in the sphenoidal bone (sella turcica), and the sphenoid bone itself forms the base of the cranial vault and the ceiling of the nasopharynx. Although some surgeons prefer to gain access to the sphenoid bone by working through the opening of the mouth, the lead author's preference is to gain access by making a small paramandibular incision through the ventral neck.<sup>50</sup> Once the sphenoid bone is reached, the bone is carefully removed precisely ventral to the pituitary. This precision requires careful localization of the gland using either CT or MRI and is absolutely necessary to avoid the surrounding structures. Once the gland is visualized, the entire hypophysis is removed by manual extirpation and suction<sup>21</sup> or by using an ultrasonic surgical aspirator.<sup>50</sup> Ideally, only the pituitary tumor would be removed and the remaining viable pituitary tissue left in place. However, the limited field of view and small size of the tumor preclude its consistent visualization. Therefore, the entire gland is removed and the patient is postoperatively supplemented with the needed hormones. The cavity that

remains in the sphenoid bone is then packed with wax or Gelfoam (Pharmacia & Upjohn), and the mucosal layers are apposed and closed using absorbable suture.

Postoperative care is divided into immediate, short-term, and long-term care. The predominant immediate concern is volume maintenance. The posterior pituitary is removed with the rest of the gland, thus removing the store of antidiuretic hormone. Therefore, the patient has little ability to concentrate its urine, and significant diuresis ensues. Serum electrolyte concentrations should be carefully monitored because severe hypernatremia can occur. Low-sodium isotonic fluids (e.g., 0.45% NaCl + 2.5% dextrose) and synthetic antidiuretic hormone (e.g., desmopressin; one drop into the conjunctival sac two to three times daily) should be administered to aid in volume maintenance. Also, a full course of a broad-spectrum antibiotic should be given because surgery is performed in a nonsterile site. Lastly, prednisone should be administered at a physiologic dosage (0.25 mg/kg PO sid or bid) as well as postoperative analgesics.

Short-term care (days 1 through 10) consists of continued monitoring of serum electrolyte concentration and administration of synthetic antidiuretic hormone, antibiotics, and corticosteroids. Also, patients are encouraged to eat and drink 24 hours after the surgery. Monitoring of tear production is necessary because keratoconjunctivitis sicca is an infrequent complication of hypophysectomy and is usually a result of trauma to the major petrosal nerves.<sup>51</sup> Because the ability to secrete thyrotropin-stimulating hormone has been removed with the pituitary, thyroxine should be administered (0.022 mg/kg PO bid). Although all other pituitary hormones have been removed as well, it is unnecessary to replace any hormones other than those described. The animal will no longer be able to breed; however, that is usually not a concern because most dogs with PDH are beyond the age of active breeding and are often already neutered.

Long-term care is minimal in most cases. Most dogs are able to form concentrated urine by day 10 after surgery. If not, continued administration of synthetic antidiuretic hormone is indicated. Thyroxine (0.022 mg/kg PO bid) and prednisone (0.25 mg/kg/day PO) will need to be given for the rest of the animal's life. Also, a biannual examination for recurrence of clinical signs and a screening test for hyperadrenocorticism are necessary to detect loss of remission.

## ADRENALECTOMY

Before adrenalectomy, corticosteroids should be administered. Excessive cortisol produced by the tumor causes negative feedback of the pituitary, which results

in atrophy of the contralateral adrenal gland. Animals without steroid supplementation may die as early as 12 to 18 hours after surgery.<sup>52</sup> Prednisolone sodium succinate (1 to 2 mg/kg IV), dexamethasone (0.1 to 0.2 mg/kg IV), or hydrocortisone (4 to 5 mg/kg IV) may be used.<sup>53</sup> If bilateral adrenalectomy is to be performed, a mineralocorticoid (e.g., desoxycorticosterone [2 mg/kg IM or SC], fludrocortisone [0.02 mg/kg PO sid]) should be initiated before surgery.<sup>54</sup> Perioperative antibiotics should be considered because of chronic steroid exposure and associated immunosuppression. Perioperative low-dose heparin therapy may also be administered to help reduce the chances for embolic events.<sup>55</sup> In addition to routine preparation of the ventral abdomen, the neck may also be prepared to harvest a jugular venograft if caval involvement is suspected. Because of the degree of surgical difficulty, two experienced surgeons may improve the chance for a favorable outcome, especially when extensive local invasion of the tumor is suspected.

Two approaches, paralumbar or ventral midline, may be used. The paralumbar approach may be used for a unilateral adrenalectomy. The advantage of this approach is adequate exposure of the gland, with minimal dissection and damage to adjacent organs (e.g., the

pancreas) during retraction. The advantages of the ventral midline approach are the ability to explore the abdomen for metastases and exposure of both adrenal glands.

Because of the number and location of small vessels feeding adrenal tumors, hemoclips and cautery are helpful for hemostasis.<sup>55</sup> The right adrenal gland lies deep to the vena cava, and its capsule may be attached to the vena cava.<sup>55</sup> In cases with tumor invasion into the vena cava, a venotomy for tumor extraction may be necessary.<sup>53</sup> Venotomy or vena cava resection requires temporary partial or complete blood flow occlusion. Atraumatic vascular forceps or Rumel tourniquets (using umbilical tape) may be used for this purpose.

Although used infrequently in veterinary medicine, venous grafting could be performed, allowing en bloc resection of the adrenal gland and affected vena cava. Recently, an autogenous jugular venous graft was used to create an extrahepatic portosystemic shunt.<sup>56</sup> Because of its similar size, the jugular vein could be grafted in the same manner as the vena cava. In some cases, excessive local invasion or metastases preclude complete resection. The surgeon should also consider placing a jejunostomy tube before closure because pancreatitis is a possible complication after surgery.

As with all dogs with hyperadrenocorticism, long-term exposure to excessive glucocorticoids can lead to delayed healing or predispose a patient to infection. The use of slowly absorbable or nonabsorbable suture material in the holding layer of the incision is recommended.<sup>55</sup>

The same glucocorticoid administered preoperatively should be repeated postoperatively at the same dosage. After 1 to 2 days of superphysiologic doses, prednisone or prednisolone may be given at a dosage of 0.25 mg/kg PO sid for 1 to 2 weeks and then slowly tapered until ACTH stimulation reveals normal cortisol release.<sup>53</sup> Normal cortisol production is usually present at 3 to 9 weeks after unilateral adrenalectomy.<sup>45</sup> Mineralocorticoid supplementation is rarely necessary after unilateral adrenalectomy. In the case of bilateral adrenalectomy, glucocorticoids and mineralocorticoids need to be continued for life. Possible early surgical complications include hemorrhage, hypoadrenocorticism, pulmonary thromboembolism, and pancreatitis.<sup>55</sup> Heart rate, mucous membrane color, capillary refill time, and electrolytes should be monitored closely after surgery. Postoperative serial blood gases may aid in early detection of pulmonary thromboembolism, especially if dyspnea or tachypnea is noted.

A postoperative ACTH stimulation test conducted within 2 to 4 days after unilateral adrenalectomy should reveal an abnormally low response. Normal or elevated cortisol values may indicate metastases, a residual adrenal

tumor, or a pituitary tumor.<sup>57</sup> If metastatic disease or incomplete tumor removal is the source of excess cortisol, mitotane therapy should be initiated and monitored with ACTH stimulation testing. Because prednisone, prednisolone, and hydrocortisone interfere with cortisol measurement, they should not be administered within 12 hours before conducting an ACTH stimulation test. In a diabetic patient, once excessive endogenous glucocorticoids are removed, the requirement for exogenous insulin may decrease. Blood glucose should be monitored closely, and a decreased insulin dose may be warranted.<sup>57</sup>

## OUTCOME

Few long-term studies are available that document the efficacy of hypophysectomy in dogs. In humans, however, pituitary surgery for treating PDH has a remission rate of 75% to 80%. Of those patients, approximately 13% have a recurrence of clinical signs related to tumor regrowth.<sup>58</sup> The only large canine study involved 52 dogs that underwent hypophysectomy for treating PDH. Forty-three dogs (80%) achieved remission, and recurrence occurred in five (11%).<sup>51</sup>

For unilateral adrenalectomies, overall operative and early postoperative mortality (within 1 month) has been reported to be anywhere from 14%<sup>44</sup> to 60%.<sup>45</sup> Causes of mortality include euthanasia resulting from extensive metastases, inadequate steroid supplementation, hemorrhage, pancreatitis, pulmonary thromboembolism, and pneumonia. A perioperative mortality rate of 21% has been reported for bilateral adrenalectomies.<sup>44</sup>

In cases of ADH, long-term complications and prognosis depend on the extent of invasion and presence of metastases, which are most common in the liver and lungs. Dogs with adenomas or localized carcinomas and minimal local invasion have the potential to be cured.<sup>15</sup> Temporary remission of clinical signs is possible even in animals with local invasion and vena cava involvement. Recurrence of clinical signs related to hyperadrenocorticism within 3 years after surgery was reported in approximately 33% of dogs with adrenal tumors.<sup>15</sup> It is also important to note that a ruptured adrenal capsule at surgery does not necessarily warrant a poor prognosis. Van Sluijs et al<sup>15</sup> reported that two of five dogs with a ruptured capsule lived at least 8 and 48 months after surgery with no evidence of recurrence. The overall cure rate for adrenocortical tumors is approximately 50%.<sup>21</sup>

It is important to note that surgical procedures for hyperadrenocorticism are difficult and carry some risk. With experience, however, they are relatively safe and offer a potential cure to a common and potentially life-threatening disease.



## REFERENCES

- Feldman EC, Nelson RW: Hyperadrenocorticism (Cushing's syndrome), in Feldman BF, Nelson RW (eds): *Canine and Feline Endocrinology and Reproduction*, ed 2. Philadelphia, WB Saunders, 1996, pp 187–265.
- Kemppainen RJ, Peterson ME: Animal models of Cushing's disease. *Trends Endocrinol Metab* 5(1):21–28, 1994.
- Behrend EN, Kemppainen RJ: Medical therapy of canine Cushing's syndrome. *Compend Contin Educ Pract Vet* 20(6):679–698, 1998.
- Peterson ME: Medical treatment of pituitary-dependent hyperadrenocorticism in dogs: Should L-deprenyl (Anipryl) ever be used? *J Vet Intern Med* 13(4):289–290, 1999.
- Reusch C, Steffen T, Hoerauf A: The efficacy of L-deprenyl in dogs with pituitary-dependent hyperadrenocorticism. *J Vet Intern Med* 13:291–301, 1999.
- Behrend EN, Kemppainen RJ, Clark TP, et al: Treatment of hyperadrenocorticism in dogs: A survey of internists and dermatologists. *JAVMA* 215(7):938–943, 1999.
- Kintzer PP, Peterson ME: Mitotane (o,p'-DDD) treatment of 200 dogs with pituitary-dependent hyperadrenocorticism. *J Vet Intern Med* 5(3):182–190, 1991.
- Bertoy EH, Feldman EC, Nelson RW, et al: One-year follow-up evaluation of magnetic resonance imaging of the brain in dogs with pituitary-dependent hyperadrenocorticism. *JAVMA* 208:1268–1273, 1996.
- Cushing H: Surgical experiences with pituitary disorders. *JAMA* LXIII(18):1515–1525, 1914.
- Rijnberk A, Kinderen PJ, Thijssen JHH: Spontaneous hyperadrenocorticism in the dog. *J Endocrinol* 41:397–406, 1968.
- Henry RW, Hulse DA, Archibald J, et al: Transoral hypophysectomy with mandibular symphysiotomy in the dog. *Am J Vet Res* 43(10):1825–1829, 1982.
- Lantz GC, Ihle SL, Nelson RW, et al: Transsphenoidal hypophysectomy in the clinically normal dog. *Am J Vet Res* 49(7):1134–1142, 1988.
- Niebauer GW, Evans SM: Transsphenoidal hypophysectomy in the dog: A new technique. *Vet Surg* 17(6):296–303, 1988.
- Meij BP: Transsphenoidal hypophysectomy for the treatment of pituitary-dependent hyperadrenocorticism in dogs. *Vet Q* 20:98–100, 1998.
- Van Sluijs FJ, Sjollem BE, Voorhout G, et al: Results of adrenalectomy in 36 dogs with hyperadrenocorticism caused by adrenocortical tumor. *Vet Q* 17(3):113–116, 1995.
- Feldman EC, Feldman MS, Nelson RW: Use of low- and high-dose dexamethasone tests for distinguishing pituitary-dependent from adrenal tumor hyperadrenocorticism in dogs. *JAVMA* 209(4):772–775, 1996.
- Behrend EN, Kemppainen RJ: Diagnosis of canine hyperadrenocorticism. *Vet Clin N Am Small Anim Pract* 31(5):985–1004, 2001.
- Feldman EC, Tyrrell JB, Bohannon NV: The synthetic ACTH stimulation test and measurement of endogenous plasma ACTH levels: Useful diagnostic indicators for adrenal disease in dogs. *JAVMA* 14:524–531, 1978.
- Widmer WR, Guptill L: Imaging techniques for facilitating diagnosis of hyperadrenocorticism in dogs and cats. *JAVMA* 206(12):1857–1864, 1995.
- Grooters AM, Biller DS, Theisen SK, et al: Ultrasonographic characteristics of the adrenal glands in dogs with pituitary-dependent hyperadrenocorticism: Comparison with normal dogs. *J Vet Intern Med* 10:110–115, 1996.
- Pennick DG, Feldman EC, Nyland TG: Radiographic features of canine hyperadrenocorticism caused by autonomously functioning adrenocortical tumors: 23 cases (1976–1978). *JAVMA* 192(11):1604–1608, 1988.
- Ford SL, Feldman EC, Nelson RW: Hyperadrenocorticism caused by bilateral adrenocortical neoplasia in dogs: Four cases (1983–1988). *JAVMA* 202(5):789–792, 1993.
- Reusch CE, Feldman EC: Canine hyperadrenocorticism due to adrenocortical neoplasia. *J Vet Intern Med* 5:3–10, 1991.
- Grooters AM, Biller DS, Miyabayashi T, et al: Evaluation of routine abdominal ultrasonography as a technique for imaging the canine adrenal glands. *JAAHA* 30(Sept/Oct):457–462, 1994.
- Saunders HM, Pugh CR, Rhodes WH: Expanding applications of abdominal ultrasonography. *JAAHA* 28:369–374, 1992.
- Kantrowitz BM, Nyland TG, Feldman EC: Adrenal ultrasonography in the dog. *Vet Radiol Ultrasound* 27(3):91–96, 1986.
- Chun TY, Wendell D, Gregg D, et al: Estrogen-induced rat pituitary tumor is associated with loss of retinoblastoma susceptibility gene product. *Mol Cell Endocrinol* 146(1–2):87–92, 1998.
- Peterson ME, Gilbertson SR, Drucker WD: Plasma cortisol response to exogenous ACTH in 22 dogs with hyperadrenocorticism caused by adrenocortical neoplasia. *JAVMA* 180(5):542–544, 1982.
- Poffenbarger EM, Feeney DA, Hayden DW: Gray-scale ultrasonography in the diagnosis of adrenal neoplasia in dogs: Six cases (1981–1986). *JAVMA* 192(2):228–232, 1988.
- Besso JG, Pennick DG, Gliatto JM: Retrospective ultrasonographic evaluation of adrenal lesions in 26 dogs. *Vet Radiol Ultrasound* 38(6):448–455, 1997.
- Voorhout G, Rijnberk A, Sjollem BE, et al: Nephrotomography and ultrasonography for the localization of hyperfunctioning adrenocortical tumors in dogs. *Am J Vet Res* 51(8):1280–1285, 1990.
- Voorhout G, Stolp R, Lubberink AA, van Waes PF: Computed tomography in the diagnosis of canine hyperadrenocorticism not suppressible by dexamethasone. *JAVMA* 192(5):641–646, 1988.
- Emms SG, Wortman JA, Johnston DE, et al: Evaluation of canine hyperadrenocorticism using computed tomography. *JAVMA* 189(4):432–439, 1986.
- Bailey MQ: Use of x-ray-computed tomography as an aid in localization of adrenal masses in the dog. *JAVMA* 188(9):1046–1049, 1986.
- Voorhout G, Stolp R, Rijnberk A, et al: Assessment of survey radiography and comparison with x-ray computed tomography for detection of hyperfunctioning adrenocortical tumors in dogs. *JAVMA* 196(11):1799–1803, 1990.
- Turrel JM, Fike JR, LeCouteur RA, et al: Computed tomographic characteristics of primary brain tumors in 50 dogs. *JAVMA* 188(8):851–856, 1986.
- Nelson RW, Ihle SL, Feldman EC: Pituitary macroadenomas and macroadenocarcinomas in dogs treated with mitotane for pituitary-dependent hyperadrenocorticism: 13 cases (1981–1986). *JAVMA* 194(11):1612–1617, 1989.
- Voorhout G, Meij BP, Van Den Ingh TS, et al: Dynamic computed

- tomography of the pituitary gland in dogs with pituitary-dependent hyperadrenocorticism [Thesis]. Utrecht: University of Utrecht; 1997, pp 205–219.
39. Love NE, Fisher P, Hudson L: The computed tomographic enhancement pattern of the normal canine pituitary gland. *Vet Radiol Ultrasound* 41:507–510, 2000.
  40. van der Vlugt-Meijer RH, Meij BP, Voorhout G: Dynamic CT of the pituitary gland in dogs [abstract]. *Vet Radiol Ultrasound* 37:483, 1996.
  41. Kooistra HS, Voorhout G, Mol JA, et al: Correlation between impairment of glucocorticoid feedback and the size of the pituitary gland in dogs with pituitary-dependent hyperadrenocorticism. *J Endocrinol* 152(3):387–394, 1997.
  42. Bertoy EH, Feldman EC, Nelson RW, et al: Magnetic resonance imaging of the brain in dogs with recently diagnosed but untreated pituitary-dependent hyperadrenocorticism. *JAVMA* 206(5):651–656, 1995.
  43. Duesberg CA, Feldman EC, Nelson RW, et al: Magnetic resonance imaging for diagnosis of pituitary macrotumors in dogs. *JAVMA* 206(5):657–662, 1995.
  44. Emms SG, Johnston DE, Eigenmann JE, et al: Adrenalectomy in the management of canine hyperadrenocorticism. *JAAHA* 23:557–564, 1987.
  45. Scavelli TD, Peterson ME, Matthiesen DT: Results of surgical treatment for hyperadrenocorticism caused by adrenocortical neoplasia in the dog: 25 cases (1980–1984). *JAVMA* 189(10):1360–1364, 1986.
  46. Feeney DA, Johnston GR: The kidneys and ureters, in Thrall DE (ed): *Textbook of Veterinary Diagnostic Radiology*. Philadelphia, WB Saunders, 2002, pp 466–479.
  47. Gookin JL, Stone EA, Spaulding KA, et al: Unilateral nephrectomy in dogs with renal disease: 30 cases (1985–1994). *JAVMA* 208(12):2020–2026, 1996.
  48. Twardock AR, Krawiec DR, Lamb CR: Kidney scintigraphy seminars. *Vet Med Surg Small Anim* 6(2):164–169, 1991.
  49. Feldman EC: Hyperadrenocorticism, in Feldman EC, Ettinger SJ (eds): *Textbook of Veterinary Internal Medicine*, ed 4. Philadelphia, WB Saunders, 1995, pp 1538–1578.
  50. Axlund TW, Behrend EN, Kempainen RJ, et al: Hypophysectomy in dogs using an ultrasonic aspirator and a new surgical approach [abstract]. *J Vet Intern Med* 15:317, 2001.
  51. Meij BP, Voorhout George, Van Den I, et al: Results of transsphenoidal hypophysectomy in 52 dogs with pituitary-dependent hyperadrenocorticism. *Vet Surg* 27:246–261, 1998.
  52. Khosa SL, Pachaur SP: Effect of bilateral adrenalectomy on blood cellular and biochemical profiles in dogs. *Indian Vet J* 13:1393–1398, 1989.
  53. Fossum TW (ed): *Small Animal Surgery*. St. Louis, Mosby, 1997, pp 401–441.
  54. Hardy RM: Hypoadrenal gland disease, in Feldman EC, Ettinger SJ (eds): *Textbook of Veterinary Internal Medicine*, ed 4. Philadelphia, WB Saunders, 1995, pp 1579–1593.
  55. Lipowitz AJ, Caywood DD, Newton CD, Schwartz A (eds): *Complications in Small Animal Surgery*. Baltimore, Williams & Wilkins, 1996, pp 294–309.
  56. Kyles AE, Gregory CR, Jackson J, et al: Evaluation of a portocaval venograft and ameroid ring for the occlusion of intrahepatic portocaval shunts in dogs. *Vet Surg* 30:161–169, 2001.
  57. Matthiesen DT, Mullen HS: Problems and complications associated with endocrine surgery in the dog and cat. *Probl Vet Med* 2(4):627–667, 1990.
  58. Bochicchio D, Losa M, Muchfelder M: Factors influencing the immediate and late outcome of Cushing's disease treated by transsphenoidal surgery: A retrospective study by the European Cushing's Disease Survey Group. *J Clin Endocrinol Metab* 80:3114–3120, 1995.

### ARTICLE #1 CE TEST

The article you have read qualifies for 1.5 contact hours of Continuing Education Credit from the Auburn University College of Veterinary Medicine. Choose the best answer to each of the following questions; then mark your answers on the postage-paid envelope inserted in *Compendium*.

1. An HDDST is conducted to differentiate between PDH and ADH in a dog after hyperadrenocorticism is diagnosed. No suppression is seen. Which of the following is correct?
  - a. The dog has PDH.
  - b. The dog has ADH.
  - c. The dog has a 50% chance of having either PDH or ADH.
  - d. The diagnosis of hyperadrenocorticism is incorrect.
  - e. none of the above
2. Which statement regarding abdominal radiography is correct?
  - a. Abdominal radiography detects at least 75% of adrenal tumors.
  - b. The presence of mineralization of an adrenal gland is pathognomonic for carcinoma.
  - c. Abdominal radiography is the preferred method for identifying bilateral adrenal tumors.
  - d. Diffuse mineralization is usually associated with adrenal neoplasia.
  - e. all of the above
3. Which statement regarding abdominal ultrasonography is correct?
  - a. Asymmetry within a single gland or between glands can exist normally.
  - b. Ultrasonography can identify unilateral or bilateral tumors and delineate bilateral enlargement due to PDH.
  - c. Adrenal parenchyma in dogs with PDH may be heterogeneous with variably sized focal areas of increased echogenicity.
  - d. Abdominal ultrasonography detects most adrenal tumors.
  - e. all of the above

4. Which of the following is a reason for differentiating between PDH and ADH?
  - a. If surgery is an option, differentiation is used to determine the type of procedure (i.e., hypophysectomy versus adrenalectomy).
  - b. For mitotane therapy, the protocol used varies depending on whether a patient has PDH or ADH.
  - c. Treatment with selegiline is not appropriate for dogs with ADH.
  - d. The prognoses for PDH and ADH vary.
  - e. all of the above
5. Calcification is noted in approximately \_\_\_\_% of adrenal tumors in dogs.
  - a. 10
  - b. 30
  - c. 50
  - d. 80
  - e. 100
6. In dogs, the pituitary tumor that causes PDH is located in the
  - a. anterior lobe.
  - b. intermediate lobe.
  - c. posterior lobe.
  - d. anterior or intermediate lobe.
  - e. anterior and posterior lobes.
7. The recurrence rate of PDH in dogs that are treated with hypophysectomy is \_\_\_\_%.
  - a. 5
  - b. 11
  - c. 25
  - d. 50
  - e. 76
8. Which of the following is not a potential complication after hypophysectomy?
  - a. diabetes insipidus
  - b. hypothyroidism
  - c. diabetes mellitus
  - d. intracranial hemorrhage
  - e. hypogonadotropism
9. Which of the following is a common problem after unilateral adrenalectomy?
  - a. glucocorticoid deficiency
  - b. mineralocorticoid deficiency
  - c. sex hormone deficiency
  - d. catecholamine deficiency
  - e. thyroid deficiency
10. Which of the following cannot be damaged while performing a hypophysectomy?
  - a. hypoglossal nerve
  - b. cerebral arterial circle
  - c. trochlear nerve
  - d. trigeminal nerve
  - e. cavernous sinus